

WHEN ORTHOPEDICS ISN'T THERE TO GIVE YOU A HAND

BILLY CAPUTO, MD RDMS FACEP
RESIDENCY DIRECTOR, ASSOCIATE CHAIR
STATEN ISLAND UNIVERSITY HOSPITAL

Lecturer Contact: wcaputo@northwell.edu
Please reach out to me with any questions or comments

QR code to lecture
Ultrasound images
and videos used in
the lecture. PDF to
Advanced upper
extremity, trunk, and
neck regional nerve
blocks

1

Caputo's 5 tips and tricks for hand injuries

USE HAND ULTRASOUND

Ultrasound is superior to x-rays for hand injuries in many cases. You can diagnose fractures, tendon function, and foreign bodies that can be missed on x-rays. A waterbath can be used and you can get high definition images without even touching an injury.

BONE

TENDON

FOREIGN BODY

2

USE THE BEST ANALGESIA


2

Almost always, the best analgesia for hand injuries involves local anesthetics. This can be done with a regional nerve block, hematoma block, or digital block depending on the injury. It's important to know the distribution of the median, radial, and ulnar nerves.

Palmar view Dorsal view


3

HAND BURNS



Hand burns can have significant morbidity. Look for circumferential burns and ensure your patient does not need transfer to a burn center. Documentation and follow up are extremely important.


FLEXOR TENDON INJURY




You can miss partial flexor tendon injuries. Make sure to check fds and fdp against resistance in all movements of the finger. Discuss and document how a partial tendon injury is possible and patient needs follow up and may require an mri.

FLEXOR TENDON INJURY

CHECK AGAINST RESISTANCE




FOREIGN BODY



Discussing and documenting a possible retained foreign body is important.


7

HF BURN




Get history about these chemicals burns and ensure it is not HF. The treatment is completely different than other chemical burns and requires recognition and prompt treatment.

HIGH PRESSURE INJECTION



These injuries can have significant morbidity and require hand evaluation and likely have to go to the operating room. External exam may not be impressive.


EXTENSOR TENDON INJURY



Partial injuries can be completed after discharge and these patients need hand follow up and may require further work up.

8

HAND FRACTURES

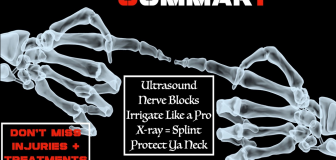


BENNETT'S FRACTURE **ROLANDO FRACTURE** **GAMEKEEPER'S THUMB**

METACARPAL FRACTURES **TUFT'S FRACTURE**

Some common hand fractures to identify. Know the acceptable metacarpal angulations and rotational deformities are poorly tolerated. When you close your fist all fingers should point towards the scaphoid.

CAPUTO'S HAND SUMMARY



Ultrasound
Nerve Blocks
Irrigate Like a Pro
X-ray = Splint
Protect UA Neck

DON'T MISS INJURIES + TREATMENTS

9
