


**TW: INTENSE AND GRAPHIC
MEDICAL PHOTOGRAPHY**

1

**PENETRATING NECK
TRAUMA**

Molly Hartrich MD, MPH
University of Illinois at Chicago



Core EM

2

DISCLOSURES

- Financial
- None



Photo by Craig Melvin

3

OBJECTIVES

- Stats and definitions
- Zones/Anatomy
- Management
 - Respiratory
 - Vascular
 - Nervous
 - Digestive/GI



Medicalpedia

4



I don't mean to offend you, but does your voice always sound like that?

5

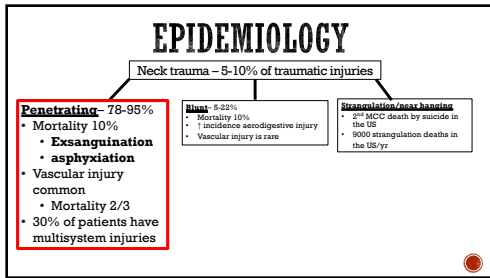


HR 149
BP 100/61
RR 21
SpO2 96

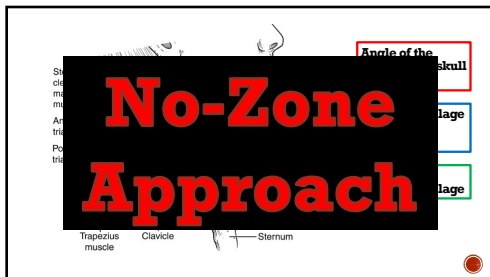
6



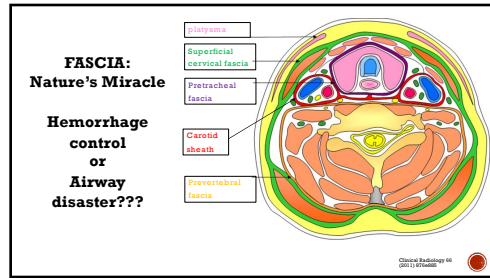
7



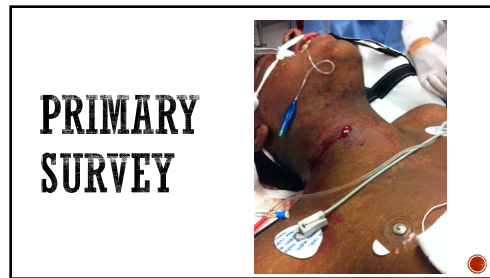
8



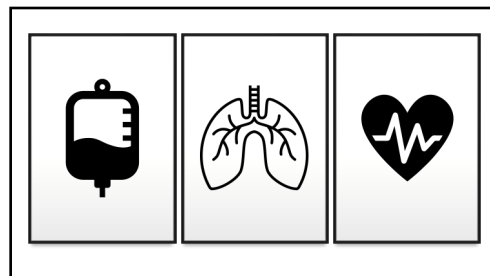
9



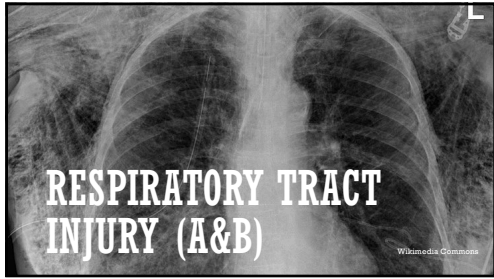
10




11



12




13



14





15



AIRWAY


- Be safe – PPE
- “Dynamic Airway”
- Early intubation
 - ED vs OR
 - For CT
- Don't make it worse
- Your comfort = ↑ success

Etomidate 0.2% (0.2 mg/mL) vs Succinylcholine 10 mg/mL

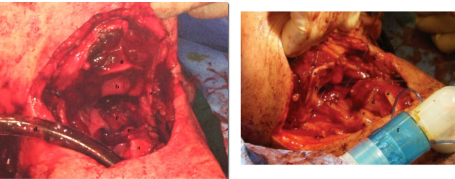
16

| | | |
|------------------------|------------------------|------------------------------------|
| Preserved Neck Anatomy | Distorted Neck Anatomy | Significant Laryngotracheal injury |
|------------------------|------------------------|------------------------------------|



Likelihood of surgical airway

17



CJEM 2015;17(1):88-93

18

BREATHING:

Case Report in Emergency Medicine, 2014, Article ID 20126

Wikipedia Commons

19

VASCULAR INJURY (C)

20

**CIRCULATION:
HEMORRHAGE CONTROL**

- **DO NOT PROBE** the injury
- Direct external pressure
- Balloon tamponade
- Resuscitate with blood products
 - BP goals - DCR
- Pre-trauma therapeutic AC reversal

Wikipedia Commons

21

SIGNS OF VASCULAR AND AERODIGESTIVE INJURY

| Hard Signs | Soft Signs |
|---------------------------------|---------------------------------|
| Airway Compromise | Hemoptysis |
| Expanding or Pulsatile Hematoma | Oropharyngeal Blood |
| Active, Brisk Bleeding | Dyspnea |
| Hemorrhagic Shock | Dysphagia |
| Hematemesis | Dysphonia |
| Neurologic Deficit | Nonexpanding Hematoma |
| Massive Subcutaneous Emphysema | Chest Tube Air Leak |
| Air Bubbling Through Wound | Subcutaneous or Mediastinal Air |
| | Vascular Bruit or Thrill |
| | Crepitus |

Rebel EM


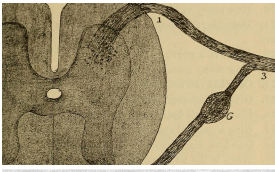
22

SECONDARY SURVEY

- To collar or not to collar?
- Look for other injuries
 - Be thorough
 - eFAST
 - CXR

Rebel EM

23

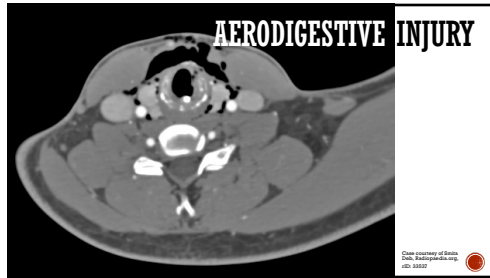



Edouard Brown-Séquard
Célebre physiologiste français
1818-1885

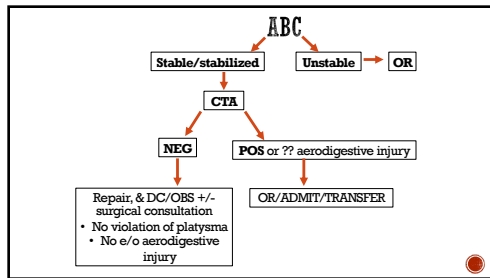
NERVOUS SYSTEM INJURY

© 2010 Rebel EM

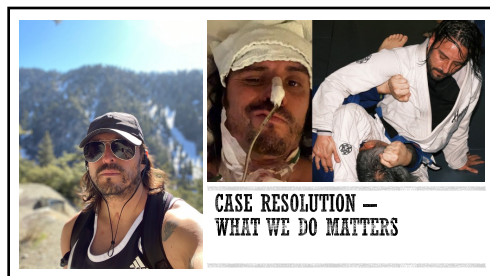24



25



26



27
