



Well... For What It's Worth
(A healthy Reassessment of What Emergency Medicine is About)

Presented By
Al'ai Alvarez, MD, FACEP, FAAEM
Director of Well-being
Co-Chair of the Human Potential Team
Process Improvement • Diversity/Equity and Inclusion
Design Thinking • High-Performance Team
No Disclosures



1



2

Objectives ...



3



4



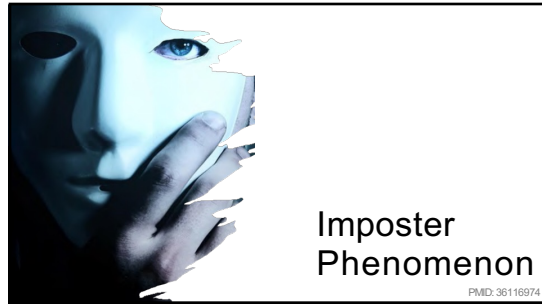5



6



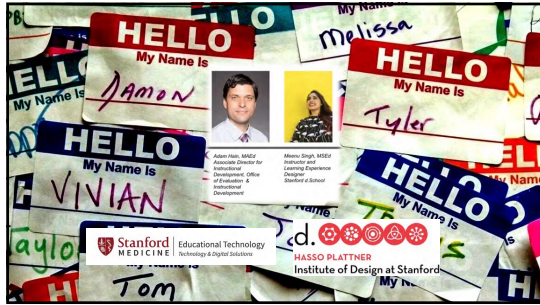7



8



9



10



11



12



Signpost Teaching

Nounou Taleghani MD, PhD
Professor, EM, Stanford

The slide features a photograph of a woman pointing at a whiteboard with a flowchart. The flowchart includes terms like 'Signpost', 'Patient', 'Family', 'Community', 'System', and 'Environment'. A portrait of Nounou Taleghani is on the right.

13



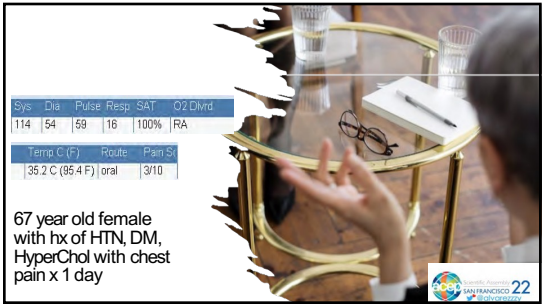
Psychological Safety

Sarah Williams, MD, MPE
Professor, EM, Stanford

PMID: 34705709

The slide shows a group of people in a clinical setting. A portrait of Sarah Williams is in the top right. The UCSF San Francisco 22 logo is in the bottom left.

14



67 year old female with hx of HTN, DM, HyperChol with chest pain x 1 day

Sys	Dia	Pulse	Resp	SAT	O2 Dlvrd
114	54	58	16	100%	RA

Temp C(F)	Route	Plan S
35.2 C (95.4 F)	oral	3/10

The slide shows a person's hand gesturing in front of a glass table. A portrait of a woman is in the top right. The UCSF San Francisco 22 logo is in the bottom left.

15



Bedside Procedures



Christine Cassidy, MD
Jacobi Medical Center



16



17

Dr. Alvarez vs. Dr. LA



Kimberly Schertzer, MD, MS
Associate Professor
EM, Stanford



18



19

Trick: Peritonsillar abscess drainage 3.0 | All the steps with added variations

April 2017 | 100 | [View Article](#)

By [Michelle Lin, MD](#)

A 22-year-old medical student came in with a right tonsillar abscess. He had all the usual signs and symptoms and was afebrile. He had a white exudate on the tonsil and a purulent discharge from the abscess. The abscess was 2 cm in diameter and was not accessible on the left.


Dr. Michelle Lin, founder of ALIEM, is a medical student at UCSF and a faculty member at the University of California, San Francisco. She is also a member of the American College of Emergency Physicians and the American Society of Emergency Medicine. She is currently a resident in Emergency Medicine at UCSF.

Trick of the Trade: Persistent Paracentesis Leakage 2.0


March 2017 | 100 | [View Article](#)

By [Michelle Lin, MD](#)


A 25-year-old man presents with 6 hours of penile pain and swelling after recreational penile injection of Trimix (alprostadil, papaverine, and phenolamine). He denies any history of sickle cell disease or penile trauma. On exam, he is in moderate discomfort and has a tumescent penis with a soft glans. You suspect the patient is suffering from ischemic, low-flow priapism. Manual compression and ice application have been attempted with no significant improvement in the patient's clinical status.




Michelle Lin, MD
Founder, ALIEM
Professor, UCSF EM



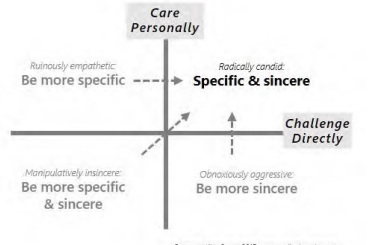
ALIEM Academic Life in
Emergency Medicine




20



Barbara Fredrickson, PhD
3:1 Positivity Ratio
PMID: 16221001



Concept: Kim Scott 2017. www.radicalcandor.com
Image: Takanji Yoshida, 2018



21



22



23



24



25
